



PATIENT

Bruno Mooney

SPECIES

Canine

BREED

Yorkshire Terrier Mix

SEX

Male Neutered

AGE

13 years

WEIGHT

16.8lbs

INTERPRETED BY

Maggie Machen Lamy,
DVM, DACVIM
(Cardiology)

IMAGING PERFORMED BY

A. Westcott, DVM

HOSPITAL NAME

Alastair Westcott,
DVM

REFERRING VET

Dr. Westcott

INVOICE

45775

DATE

11/17/25

PRESENTING CLINICAL SIGNS

History: Presented for monitoring for a seizure disorder, dental disease, presumptive osteoarthritis, and heart murmur noted at the last visit (Sept 20). The owner also reports intermittent coughing and sneezing throughout the past week, though no obvious respiratory distress has been observed.

-Abnormal PE/Chem/CBC/UA Results: Bilateral mature cataracts, dental disease grade III/VI systolic murmur PMI left apex but also on right. Mild hypertension: 170mmHg. ECG showed tall R waves. CXR: NSF.

ECHOCARDIOGRAM FINDINGS

2D, m-mode, color flow and doppler imaging is available. Mild diffuse thickening of mitral valve leaflets with mild prolapse into the left atrial lumen. Mild eccentric mitral regurgitation with no left atrial dilation. Normal MR velocity. The LV is decreased in size with increased wall thickness. Adequate myocardial function. The tricuspid valve appears normal with mild tricuspid regurgitation. Velocity consistent with early pulmonary hypertension. Normal right atrial and ventricular diameter and morphology. The pulmonic and aortic valves are normal in morphology and mobility. Normal pulmonic and aortic outflow velocities with laminar flow. No obvious aortic and trace pulmonic insufficiency. No pericardial or pleural effusion noted. No obvious cardiac masses.

CARDIAC CHART

CANINE CARDIAC PARAMETERS	MR VMAX (m/s)	TR VMAX (m/s)	LA/AO (Boon method)	LA/AO (Heart Base; Swe)	FS (%)	EF (%)	EPSS (cm)
NORMAL PARAMETER	4.5-5.5	<2.7	1.3	<1.6	28-40	40-100	<0.6
PATIENT	4.8	3.0	NM	1.3	44	80	NM
CANINE CARDIAC PARAMETERS	HR (BPM)	AV VMAX (m/s)	PV MAX (m/s)	BODY WEIGHT (kg)	LA 2D short axis Base view (cm)	LVIDd Avg; 2D and m-mode short axis (cm)	LVIDs Avg; 2D and m-mode short axis (cm)
NORMAL PARAMETER	50-100	0.7-1.7	0.7-1.6	BELOW	BELOW	BELOW	BELOW
PATIENT	NM	1.5	1.0	7.6	1.5	1.8	1.0
*Normal chamber parameters expressed as a mean value (SD)				3	1.27 (5.3)	2.46 (2.46)	1.36 (5.5)
BODY WEIGHT DEPENDENT PARAMETERS				5	1.40 (4.5)	2.74 (5.2)	1.60 (4.7)
*Note: All measurements based upon multi-modal images and methods. An average value is reported.				10	1.50 (3.8)	3.27 (3.5)	2.06 (3.1)
				15	1.83 (2.0)	3.71 (2.4)	2.43 (2.1)
				20	2.02 (1.9)	4.14 (2.2)	2.80 (2.0)
				25	2.18 (2.4)	4.48 (2.9)	3.10 (2.5)
				30	2.33 (3.3)	4.83 (3.9)	3.39 (3.4)
				35	2.48 (4.3)	5.17 (5.0)	3.69 (4.5)
				40	2.62 (5.2)	5.48 (6.1)	3.96 (5.4)
				50	2.88 (7.1)	6.07 (8.3)	4.46 (7.4)

INTERPRETATION OF THE FINDINGS & FURTHER RECOMMENDATIONS

Chronic degenerative valve disease causing mild mitral and tricuspid regurgitation. Lack of significant left atrial enlargement indicates the current risk for complication is low. Early pulmonary hypertension is noted, which is of unknown significance in a dog without chronic respiratory disease. Simple monitoring is advised. Finally, the appearance of the LV (small chamber with increased wall thickness), is most consistent with pseudohypertrophy and baseline lab work is recommended. No additional issues are seen.



PATIENT

Bruno Mooney

SPECIES

Canine

BREED

Yorkshire Terrier Mix

SEX

Male Neutered

AGE

13 years

WEIGHT

16.8lbs

INTERPRETED BY

Maggie Machen Lamy,
DVM, DACVIM
(Cardiology)

IMAGING PERFORMED BY

A. Westcott, DVM

HOSPITAL NAME

Alastair Westcott,
DVM

REFERRING VET

Dr. Westcott

INVOICE

45775

DATE

11/17/25

In a dog with no significant left atrial enlargement, no cardiac medications are clearly indicated. Assessment of progression in the future will help predict long term prognosis, which is highly variable at this stage (B1). Omega fatty acid supplementation and mild salt restriction may be of some long-term benefit. Monitor for development of a cough, labored breathing, exercise intolerance or collapse episodes.

Anesthetic risk is considered mild if needed. Cardiac protective drug choices (opioid/benzodiazepine premedication, propofol or alfaxalone induction, isoflurane gas) are recommended. Pre-oxygenate for 5-10 minutes prior to induction. Monitor for arrhythmias, hypotension, and hypoxia both intra and post-operatively and intervene as necessary. Mild IV fluid restriction is recommended to avoid fluid overload. Avoid heart rate stimulating drugs such as atropine unless clinically indicated.

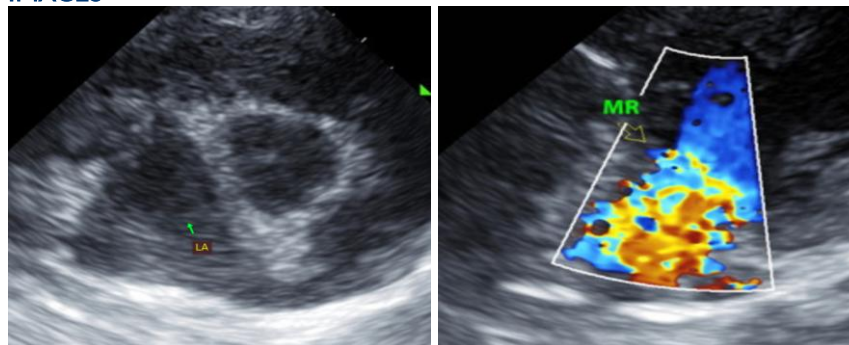
The reported blood pressure is elevated and should be reassessed for accuracy particularly given no reported clinical signs of severe hypertension (retinal changes, etc.) on echo. Ideally obtain serial measurements in a controlled, low stress environment and continue until 3 consecutive readings plateau within 5mmHg of variability. If persistently >180mmHg despite a relatively calm demeanor, recommend institution of amlodipine to effect. Additionally, if deemed accurate, screening for predisposing underlying causes of SHT is recommended (Cushing's, PLN, adrenal tumor, etc.), as primary disease is relatively uncommon and a rule out diagnosis.

PLAN

Baseline lab work recommended. Reassess BP as discussed.

Recommend conservative monitoring with a recheck echocardiogram in 6 months, sooner if any development of clinical signs.

IMAGES



The information and recommendations provided are based on the images presented by the referring veterinarian. No evaluation can be communicated regarding pathology that was not visible in the image/video clips provided.

Thank you for this referral. This report was generated using transcription software, and minor dictation errors may be present. If the clinical or image interpretation does not parallel your findings or if I can be of any further assistance, please contact me.

Maggie Machen Lamy, DVM
Diplomate of the American College of Veterinary Internal Medicine (Cardiology)
info@sonopath.com